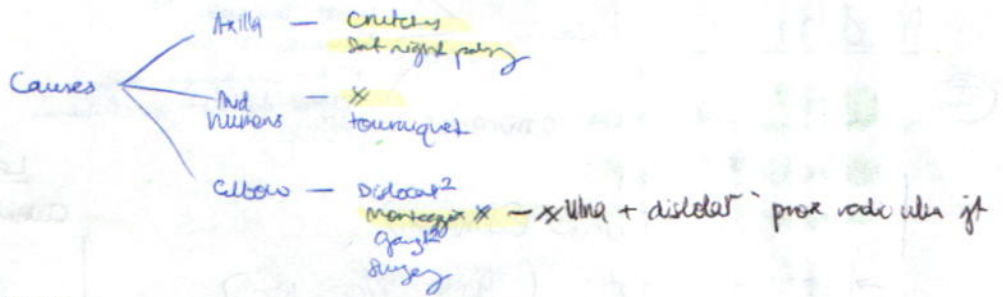


# PERI NR

## Radial Nr (C5-C8)



### ⊕ Wrist drop

Waste - extensors' forearm  
triceps  
trophic Δ

### Power

Ext ← Thumb  
wrist

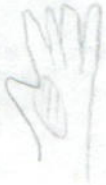
Supinator (extended to eliminate triceps)  
BR

Triceps

Reflexes

TJ  
BR

### Sens



## Ulnar Nr

⊕ Wrist - Ulnar : inc 1<sup>st</sup> dorsal i/o (flex MCP → stretch etc)

h-thenar eminence

forearm (ulna side) + valgus/varus + mobility' Nr

Abd' MCP - Little finger - 4<sup>th</sup> + 5<sup>th</sup> finger

Ulnar claw hand (e higher e lat, e less obvious e deformity  
- Ulnar paradox)

Snap → traumatic results  
Tender  
Thicken  
Paraesthesia


Trophic Δ - ulnar  
brittle nail

skin : waken, drier, vasodil, abs sweat  
table : grab paper

### Power

PAD - hard flat  
- spread open fingers  
1<sup>st</sup> dorsal i/o

### ① Dorsal I/O



Abd' digiti minimi

Fronment's test  
(add pollicis)

### Sens

Post cut branch - arise 6cm prox to no unaffected in wrist let platform

FCU - feel tender in wrist

FDP - DIP jt  
(stabilize middle phalanx)

Median N<sub>r</sub>

Causes ← Carpal tunnel syn, x, dislocat  
 Wrist lacerate  
 Forearm x  
 PT N<sub>r</sub> entrapment syn  
 Elbow dislocat<sup>2</sup> in children  
 (APB exp)

⊕ Wrist thenar emirence  
 → Benedic<sup>t</sup> sign  
 Ape-like thumb (d<sup>ist</sup>man)  
 → Forearm wast (Ant i/o N<sub>r</sub>)  
 Tropic Δ - Atrophy pulp, crack. nails  
 Sen loss → Burns (cigarette)

Power

Abd pollicis brevis → Pen-touch test

Oschner's clasp test - FDS  
 FPL  
 FDP - index finger } stabilize PIP  
 Pronator Teres

Pinch deformity → Ant i/o N<sub>r</sub> Syndrome

Level injury

Cubital fossa	Benedic <sup>t</sup> sign Ape-like hand
Forearm	Oschner's clasp test (FDS) Pronator Teres Ant i/o N <sub>r</sub> - FPL FDL (2/3/4/5)
Wrist	Pen-touch test (APB)

Sensory

Tropic Δ - Dry, scaly skin  
 Nails crack easily, atrophy pulp  
 Loss sensat - lat 3 1/2 fingers  
 Vasomotor Δ - Warmer & drier  
 Absence sweat → slide pen across surface

Carpal Tunnel Sign

Tinel's

Phalen's (1-2 min)

Slide index across palm - ? ↑ °C (vasodil)  
 ↑ frict<sup>2</sup> - ↓ sweat

Δx: Pancoast's  
 Cerv rib

Flex  
 Oppost

Axillary N<sub>r</sub>

Causes: Shoulder dislocat<sup>2</sup>  
 x 'any neck' humers  
 Badly adjusted crutch } Compress on axillary N<sub>r</sub> in quadrilat space

⊕ Deltoid wast - Flatten

Power

Deltoid

Sens



Uplat out N<sub>r</sub> arm (for post back)  
 → also supplies teres minor

# Ulnar Nerve

**Causes:**

- Elbow** - Entrapment b/w 2 heads' FCU (Fibrous tunnel)  
 Supracondylar\* (Cx: Cubitus valgus) → Tardy ulnar nr palsy  
 Direct trauma  
 OA, ganglion
- Wrist** - Laceration  
 Ulnar tunnel signs: Guyon's canal  
 Ganglion  
 \* hook hamate

O/E

ⓐ of ⑤ hand

① **Wasting** - ulnar side forearm  
 - atrophic emersion  
 - i/osseus → esp 1st D/O

② **Ulnar claw hand** (\*Ulnar palsy)  
 - 2° higher 2° less, 2° less obvious 2° deformity

③ **Trophic Δ** - ulcer, brittle nail  
 skin - drier, warmer, vasodil, abs sweating  
 ↓  
 ① Friction test (Hamman)  
 ② sweat test: Ninhydrin powder (Moberg test) → black if sweat

## Power

- ① FCU  
 FDP (med 2)
- ② Abd digiti minimi **Cathedral sign**
- ③ Intraosseous - Dorsal  
 - Palmar
- ④ Froment's test (adductor pollicis)



## Sensation

Pin-prick

## Special tests

Mobility' Nr behind medial epicondyle: Flexion elbow  
 → "Snap" over med epi  
 (Traumatic ulnar neuritis)

Ix:

① NCS

ΔDx

① Brachial plexus les<sup>n</sup> - C8, T1

② Cervical spondylosis - C8 nr root (C7-T1 vertebrae)

(T1)

① Klumpke's paralysis - ① Wasting: thenar x hyperextension

Coarctation injury  
- ~~brachial~~  
dystocia

② T1 dermome

Ass: Horner's syndrome

③ C6 Fib

" spondylosis

④ NF

○ Lung A at apex

Ix - Nr lei

① NCS

② Histamine test (Barrely's): 1 drop 1% histamine → prick skin

Histamine type flare → prox to post ganglion: bad Rx

Absent → postganglion damage

C8, T1 - Unilat

Nr - ulnar & median

Brachial plexus - Klumpke's  
C8 n6, cancer - apex

Ant root - C8 spondylosis

Ant horn ⊙ - MND (ALS)  
Poliō