

# BREAST EXAM

Introduce "may I examine you, please?"  
 Undress down to waist  
 'which breast is the problem?' 'where in the breast is the problem?'

Gen

Expose top 1/2 trunk

- ① Sit up
- Hands behind head
  - Press on hips (contract pect)
  - Bend forwards

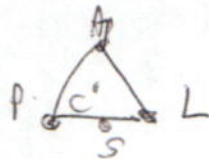- ①
- Size** - Symm
  - Skin** - Scars, Dimpl/Pucker, Discolourat<sup>2</sup> / peau d'orange / Ulcerat<sup>2</sup>, Visible veins / Telangiectasia, Nodules, Atrophy } Pericardial m - well demarcated
  - Areolae** - Colour
  - Nipple** - Retract<sup>2</sup>, Ulcerat<sup>2</sup>, Symmetry ? displaced / deviated, Discharge, Dupuyat<sup>2</sup>, ? Paget

② Lie down - one hand behind neck - pillow support

- ① 4 quadrants  
 Axillary tail
- ② breast 1st → Flat hand  
 ↓  
 Finger & thumb
- Areola  
 Nipple
- both fingers Squeeze → ? Discharge

hands at side - hips

**Axillary LN**




(30% P patients - ✓ palpable LN)  
 (40% axillary LN - Impalpable LN)

- Sit up
- Contract pm
  - press on my shoulder
  - & fr behind

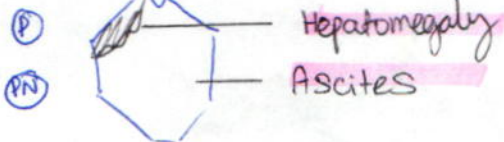
③ Sit up

- ① **Supradavicular LN**  
**Infraclavicular / Interpectoral (Rotter's)**  
 (cervical)

**Vertebrae - tenderness**



④ Lie down



Straight leg raise  
 AJ

③ - nodules in pouch / Douglas

ΔDx

- ① CF
- ② Cyst
- ③ Fibroadenoma

④ Others — Traumatic<sup>n</sup> : Fat necrosis  
 Other cyst : Galactocele  
 Chr abscess  
 Cystadenoma  
 Retention cyst


Other tumours : Duct papilloma  
 Sarcoma

Chest wall swelling : Rib fracture  
 TB  
 Lipoma  
 Erythema  
 Mondri's DC (off ven thrombosis)

~~... ..~~

~~... ..~~

~~... ..~~



- ④
- ⑤
- ⑥

# THYROID

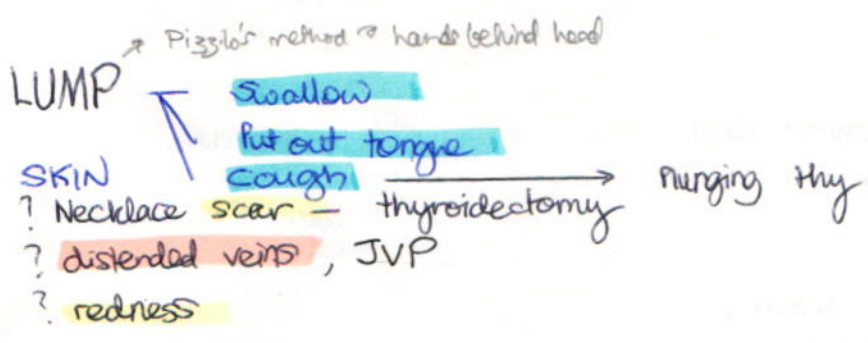
GEN

Thyrotoxic - agitated  
Myxoedema - lethargic

Shake hands  
- warm, sweaty

NECK

(I)



(P) fr behind LUMP	Site Size Sur	Contour Consistence Colour	°C Tenderness Transilluminable <b>THRILL</b>	Fluctuancy Fixity LN	Pulsatile Expansile Reducible
--------------------	---------------------	----------------------------------	---	----------------------------	-------------------------------------

LN - Cerv  
Supradavicular  
Pretracheal

\* Carotid A - if pushed laterally ⇒ large heugh  
SCM fct (Sir James Bonzie's sign)

\* Trachea - deviat<sup>d</sup>  
Thy cart

WHO grade

Grade 0	No palpable/visible goitre
1A	Palpable only
B	" + visible neck iv scar
2	visible in @ post <sup>r</sup>
3	large " fr distance

(PN) Retro-sternal goitre

(A) Bruit (Hard on lat lobe - ↓ carotid puls<sup>d</sup>)  
(Ven hum → IJV occluded)

## OBS

Emberson's - suffur<sup>d</sup> face, giddiness/syncope

Kocher's - push together

Extens<sup>d</sup> head - ? stridor

Stridor

SCM fuct<sup>d</sup>

If thyroidectomy scar present:

(1) Recurrent laryngeal nr - Cough  
Ext " " - 'Eee'

(2) h-Ca<sup>2+</sup> - Chvostek's sign  
Trousseau's sign (inflate above DBP for >3min)  
→ Facial muscle twitches  
→ tetany spasms

# Thyrotoxicosis

# Myxoedema (h-thy)

Gen

Thin  
Sweaty  
Nervous

Fat  $\rightarrow$  supraorbital & CT  
Peaches & cream colour  
Coarse dry skin  
Inelastic  
Brittle hair

Hands

Onycholysis (Plumbeous nails)  
Thy acropachy

Tremor

Warm, moist, sweaty  
Palmar erythema

Cold  
Puffy & spade-like

Peri onychia  
Anaemia

HR —  $\uparrow$   
AF

Head

(NS)

Trousseau's  
Prox myopathy

Eyes —

Proptosis

Lid retract<sup>n</sup> / lag / Frightened / Infrequent blink

Chemosis / Conj. inject<sup>n</sup> / oedema  
Soft tissue shell eyelids

Ophthalmoplegia  
(lateral rectus, vertical gaze)

— HORNER'S

Parotid — Chvostek's (if  $\checkmark$  thyroidectomy)  
 $\rightarrow$  tap under ear  
+ twitch face

Voice

Eye lids — swollen & heavy  
Eyebrows — lost in lat 1/3

Slow deep hoarse voice

CVS

Extrasyst  
AF  
murmur — systolic

Pericardial effus<sup>n</sup>

RS

Pleural "

LL

Pretibial myxoedema — yellow-brown  
leath-like  
swollen  $\rightarrow$  follicular  
on feet  
enlarged orange-ped  
Hirsutosis

Non-pit<sup>r</sup> oedema

(NS) — AF Fast relaxat<sup>n</sup> phase  
Squat up & down

Slow relaxat<sup>n</sup> phase

Inverted supinator

O/E: DM

GEN INSPECTN

Weight Obesity  
Hydrat<sup>2</sup> delto  
endocrine facies - Cushingoid  
Acromegaly  
Pigmentat<sup>2</sup> - Haemochromatosis  
RR - Kussmaul's respirat<sup>2</sup>

LEGS

(I) Dermatology

Neurobiosis lipoidica diabetorum  
Granuloma annulare  
Diabetic dermopathy - small sunken brownish scars (shins)  
Eruptive xanthomas (buttocks & shoulders)  
Bulla -> Blisters  
Vitiligo - generalized

Vasc

Shiny, scaly  
loss hair  
I area  
Gangrene  
leg ulcer

Infect<sup>2</sup>

Onychomycosis  
Boils  
Cellulitis  
Candidiasis

NS

Atrophy - quads  
Charcot's jt

Gx'Rx

Fat atrophy / Atrophy  
Inject<sup>2</sup> sites

(II)

Capillary refill

- poor

Temperature

- cold

Pulses

Aorta  
Common iliac  
Fem  
Pop  
DP  
PT

? A wall - hard  
Bruits  
Response - exercise  
\* Peroneal

NEURO

Tone  
Power -

Fem & Common Peroneal mononeuritis  
Amyotrophy

Reflexes -

KJ  
AJ + Babinski response

Sensat -

Vibrat<sup>2</sup>  
Propriocept<sup>2</sup>  
(light touch / Pin-prick)

UL

I Dermatology - GA  
~~Acanthosis nigricans~~

Infect<sup>2</sup> - Paronychia  
Cellulitis

P Inject<sup>2</sup> sites

Pulse - Radial

BP - 1 yr stand

? postural drop

HEAD

Eyes

Visual acuity

(Shape lens Δ<sup>c</sup> Hyperopia & H<sub>2</sub>O retent<sup>2</sup>)  
→ myopia

Pupils

~~Argyll Robertson pupils~~

Ophthalmoscopy

Rubeosis iridis

Cataracts (senile deposit<sup>2</sup>)

Fundus

Background: dot, blot, hard exudate

Pre-pro: soft exudate, ven loophead

Pro: Neovase

Pre-ret vitreous haem  
Retinal detachment

— Laser photocoag.

macular oedema  
maculopathy → focal, diffuse, cystic

III

~~Pupils~~

Nr palsy

flaccid

Eye-down/out

Ears

Malignant otitis externa

VII Nr palsy

Mouth

Candidiasis

Rhinocerebral

~~mucor mycosis~~

(periorbital & perinasal swell  
& cranial Nr palsies)

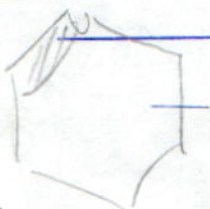
NECK

Carotid

R=L  
Bruit

~~Diabetic sclerodactyly~~

ABD



~~Hepatomegaly~~: fatty liver  
haemochromatosis

Inject<sup>2</sup> sites

Special

① Urine Dipstick +

Glucose  
Ketones  
Protein

② [Glu] random

S:G < 1.002 : CRF  
> 1.025 : de keto DM

SG 1.002 1.00 1.030 1.200 !!  
osmolality