

CVS (ly at 45°)

Well-look young man ly comfortably in bed

GEN

Marfan's, Turner's, Down

Ank. spondylitis

Acromegaly

* SOB, cyanosis

Cachexia, jaundice

copy pt

UL

Hands - Nails clubbed splinter haemorrhage Nictite stain

- Rulp Osler's Jareway Periapaposis

- Skin crease Anaemia

PR - rate, rhythm, amplitude Char: bounding/collaps

- vessel wall → thickened → ↑ intensity ↑ med. layer alternans

- radial-radial ineq
- fem

Elbow - xanthomata (II)

BP ly < ins exp > 10mmHg - asthma
stand > 15 SBP > 10 DBP
constrictive pericarditis pericardial effus²

FACE

Xanthoma Jaundice (CLF, prosthetic valve)

Sclerae Conjunctiva Pallor

Pupils Argyll-Robertson

Cheek - malar flush (MS, PS) RLM flou^r

Mouth - tongue ctm apaposis, enlarged

palate high arch (Marfan's)

dentit² petechiae (IE)

micosa

NECK JVP (R) high char Kussmaul's sign (↑ ins)

Carotids pulse char (R) (L) small vol slow rising

Hold up then breath

CHEST

(I) Scars / Pakenaker Deformity

AB - posit² char

Abn pulsat²

(P) AB (diff arm 90° → splayntic) Abn pulsat² - Rv heave, parasternal impulse, P₂ tap

(PS) Thrill (P₁ tense) (S)

(A) (M) (F) 3L SB (cert's pt) (A) (P)

? S₃, S₄? S₃/S₄ mmmur? change^c ins/exp

(L) lat pos AB - ? tapp (ms) Apical thrill MPM - 1cm med to apex sit up & full exp (A) 3L E (A) stern edge - thrill Valsalva

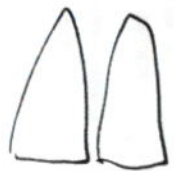
BACK

(I) Scars Deformity

(P) Sacral oedema

(PS) Pleura effus²

(A) ↓ BS ins crackles murmur - coarse



ABD (ly on 1 pillow)

(I) Liver hepatomegaly: FVF pulsatile: PR spleen splenomegaly: IE Aorta aneu

(PS) Ascites - PR

(A) Aorta Iliac renal

LL

Fem pulse radio-fem delay bruit

Peri pulses +++ bound^r ++ (A) + (P) 0

SOA Homans' sign creptic Δ - hair loss, ulcers skin temp cold limbs

Toe Clubb^r IE Cap refill t Buerger's test

Varicose V cough impulse test, Tapp^r test Trendelenburg Perthes Chr venous stasis

OTHER

Temp chart

IE
MIE
myocarditis

FUNDI

IE → Ketts spot
Hemstie retinopathy

Urine analysis

haematuna → IE



BACK

APD (up - Br / yellow)

APD (up - Br / yellow)

APD (up - Br / yellow)

APD (up - Br / yellow)

APD (up - Br / yellow)

APD (up - Br / yellow)

APD (up - Br / yellow)

APD (up - Br / yellow)

APD (up - Br / yellow)

APD (up - Br / yellow)

APD (up - Br / yellow)

APD (up - Br / yellow)

APD (up - Br / yellow)

APD (up - Br / yellow)

APD (up - Br / yellow)

APD (up - Br / yellow)

APD

APD

APD

APD

APD

APD

APD

APD

APD

APD

APD

APD

APD

APD

APD

APD

APD

APD

APD

CVS

Gen ?well-looking
Tachypnoeic

Back



Crackles - basal
Pleural effar

Hands - Nail : Nicotine stain
Splinter h'age
Clubbing

Palms : IE - Osler's nodes
Janeway les → red, raised tender nodule
→ non-tender erythematous macule (✓ bacteria)

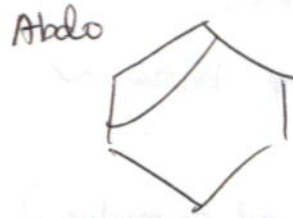
Facial oedema

HR - (PR) ?reg vessel wall Vol/char

BP - ?drop
?paradox

H&N - Xanthelasma
Jaundice
Anaemia

Malar flush
Ckt cyanosis
Dentition



Liver (PN)
Edge ?palpable
Ascites - shifting dullness
Spleen
(AAA)

Neck - JVP ht (light)

Carotid pulse char - waveform
?pulsat
bruit ↓ slow rising → small

LL

Swelling
Pulses

- Ask ① Temperature chart
② FWTU
③ Fundoscopy

Chest

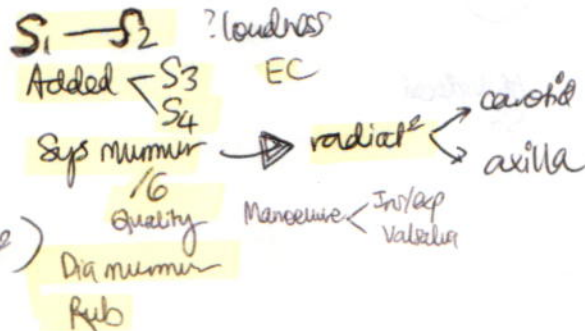
(E) Scars / Pacemaker
→ Thoracotomy

AB - ?visible
AB - Hydropic
Hicnatic

Parasternal heave / P₂ tap
Sys thrill

(A) (Timing e murmur)

Diaphragm: Apex
3LSE (Valsalva)
2LSE



Bell : Turn Lt → Apex (N) Exptat
3LSE + Valsalva

Sit up → lean forward in exp:
?EDM

Clubbing

- ① Familial / Idio
- ② CVS - Cyanotic H.D
IE
- ③ RS - lung CA (small cell)
Chr pneumoniae - BE
Abscess, Empyema

Idio (D) fibrosis

- ④ GIT - Crohn's esp ileum ~
IBD
Coeliac D
- ⑤ Thyrotoxicosis (Thyroid acropachy)

Unilat - Bronchial A-V aneur
Axillary artery

Xanthoma

- tuberous: elbow
knee
- eruptive: forearm
buttock { Hered-familial
- tender: extensor hands
Achilles ankle-plantar heel

Severity

(AS)
↓ prolonged
LNT
Chill

(MR)

Ab displaced
S3

RS (Sitt up)

GEN

Cushingoid
Nasal prong/Hudson mask

Respirat²

RR
Depth chest expans²
Breath pattern
acc musc
SOB, stridor

Cough

Hoarseness
Cachexia

Char
Sputum
type: purulent/mucoid
? bld
(Sputum mg)

HANDS

Clubbing, HPO
Nicotine stain

Nails

Pulp

Peri cyanosis

Skin crease

Anaemia

Weakness → Finger abd

FLAPP TREMOR

HR

BP pulsus paradoxus

FACE

Cheeks - Telangiectasia
Moon-face → Steroid Rx
Cushingoid

Eye

Homer's
Anaemia / polycythemia

Nose

Mouth

Throat Sore throat
Tongue CRT cyanosis
Teeth

Sinus

Sinusitis

Obs sleep apnoea (chise, reced chin, small pharynx, short thick neck)

NECK

JVP

Trachea

cricoid → manubrium distance
displaced → ?UL
on thy cart: push down
on sternal angle

LN - cerv

supradavicular

Pemberton's sign

Subcutan emphysema

CHEST

POST

⊕ Shape

Barrel-shaped
Pectus carinatum
excavatum
Harrison's sulcus
Kyphoscoliosis

Les²

Scars - Rx
Radiotherapy → poikiloderma
Prominent V - SVCs < neck / used at v

Movement UL expans² ← ? delay
↓ move

⊕ LL expans² [D > 5cm] ? asym
Vocal fremitus

Ribs

⊕ (Diaphragm tidal perc²?) ? dullness in base
intensity

⊕ BS

wheeze
Crackle
Fric² rub
Vocal resonance
say '99' '123'
whisper '99'

Early vs Late vs
fine - Rales (low)
medium - LVF
coarse - Bronchectasis

ANT

⊕

⊕

RV heave

⊕

LN - axillary
liver - ? ptosed

TESTS

Peak flow meter

FET → near = stethoscope or = stetho
Ins t > 30 → COPD

VC - count - test

BREAST & Axillary LN

CVS

loud P₂ - RLM ↑↑↑
SVP

ABD

liver ptosis
hepatosplenomegaly - CA

LL

swell / oedema
cyanosis
DVT

OTHER

Temperature

SaO₂

